

# The Fragile X Premutation Presenting as Essential Tremor

Maureen A. Leehey, MD; Renato P. Munhoz, MD; Anthony E. Lang, MD; James A. Brunberg, MD; Jim Grigsby, PhD; Claudia Greco, MD; Sebastian Jacquemont, MD; Flora Tassone, PhD; A. M. Lozano, MD, PhD; Paul J. Hagerman, MD, PhD; Randi J. Hagerman, MD

**Context:** The fragile X premutation has recently been reported to be associated with a neurodegenerative syndrome, chiefly characterized by intention tremor, gait ataxia, and executive cognitive deficits in men older than 50 years. Essential tremor is a frequent cause of tremor in elderly patients and in some cases is associated with impaired tandem gait and cognitive deficits.

**Objective:** To describe 2 fragile X carriers whose clinical presentation mimicked essential tremor.

**Design:** The 2 patients described herein underwent neurologic examinations by experienced movement disorders neurologists, magnetic resonance imaging, and fragile X gene, messenger RNA, and protein analyses. One underwent detailed neuropsychological testing.

**Settings:** Patients were studied at 2 large university movement disorders clinics.

**Patients:** Both patients were white men older than 50 years who had been diagnosed as having essential tremor and then found to be fragile X carriers.

**Results:** Besides disabling intention tremor, the 2 patients had impaired tandem, generalized brain atrophy, and unusual bilateral T2 middle cerebellar hyperintensities on magnetic resonance imaging. The patient who underwent neuropsychological testing had frontal executive deficits. Both patients had elevated fragile X mental retardation gene 1 messenger RNA and reduced fragile X mental retardation 1 protein levels.

**Conclusion:** The fragile X carrier state may underlie the clinical findings in some older men diagnosed as having essential tremor.

*Arch Neurol.* 2003;60:117-121

From the Departments of Neurology (Dr Leehey) and Medicine (Geriatrics) (Dr Grigsby), University of Colorado Health Sciences Center, Denver; Division of Neurology, Department of Medicine (Drs Munhoz and Lang), and the Division of Neurosurgery (Dr Lozano), University of Toronto and Toronto Western Hospital, Toronto, Ontario; Departments of Radiology (Dr Brunberg), Pathology (Dr Greco), and Biological Chemistry (Drs Tassone and P. Hagerman), University of California at Davis School of Medicine, Davis; and M.I.N.D. Institute, University of California at Davis Medical Center, Sacramento (Drs Jacquemont and R. Hagerman).

**T**HE FRAGILE X premutation has recently been reported to be associated with intention tremor in older men.<sup>1</sup> Besides the disabling intention tremor, these men develop a progressive neurologic syndrome characterized by cerebellar gait ataxia, executive cognitive deficits, mild parkinsonism, erectile dysfunction, peripheral neuropathy, and generalized brain atrophy. We describe 2 fragile X carriers whose clinical presentation mimicked essential tremor (ET).

## REPORT OF CASES

### PATIENT 1

A 68-year-old, right-handed, retired municipal consultant had onset of bilateral hand shakiness with action at age 58 years. The tremor slowly progressed, and he was diagnosed as having benign ET at age 65 years. By age 66 years, the tremor was occasionally present at rest, and by age 68 years, it interfered with eating, shuffling

cards, turning pages, bowling, and handwriting.

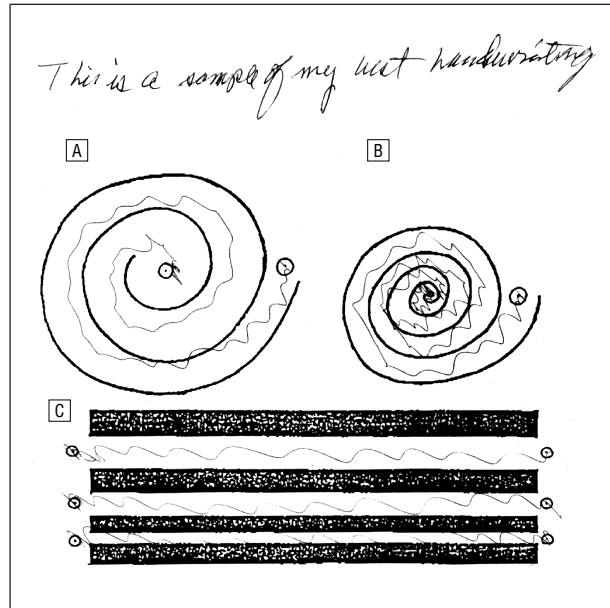
Atenolol, prescribed for hypertension, reduced his tremor moderately; alcohol had no effect. He admitted experiencing forgetfulness since age 66 years and denied balance or gait difficulties. Erectile dysfunction started at age 61 years, 4 years after a transurethral prostatic resection.

His medical history was notable for hypertension, hyperlipidemia, and hypothyroidism. He also received the following medications: atenolol, nifedipine, pravastatin sodium, tamsulosin hydrochloride, levothyroxine sodium, guaifenesin, and aspirin. He had a 30 pack-year history of smoking and drank alcohol only occasionally. Childhood and adolescent development were normal and school performance was excellent.

There was no family history of tremor or movement disorder. His mother died in her late 60s with autopsy-confirmed Alzheimer disease. His maternal grandmother also had dementia. His oldest daughter's third son has fragile X syndrome, with a sim-

ian crease, motor delay, head banging, hand flapping, and mental retardation.

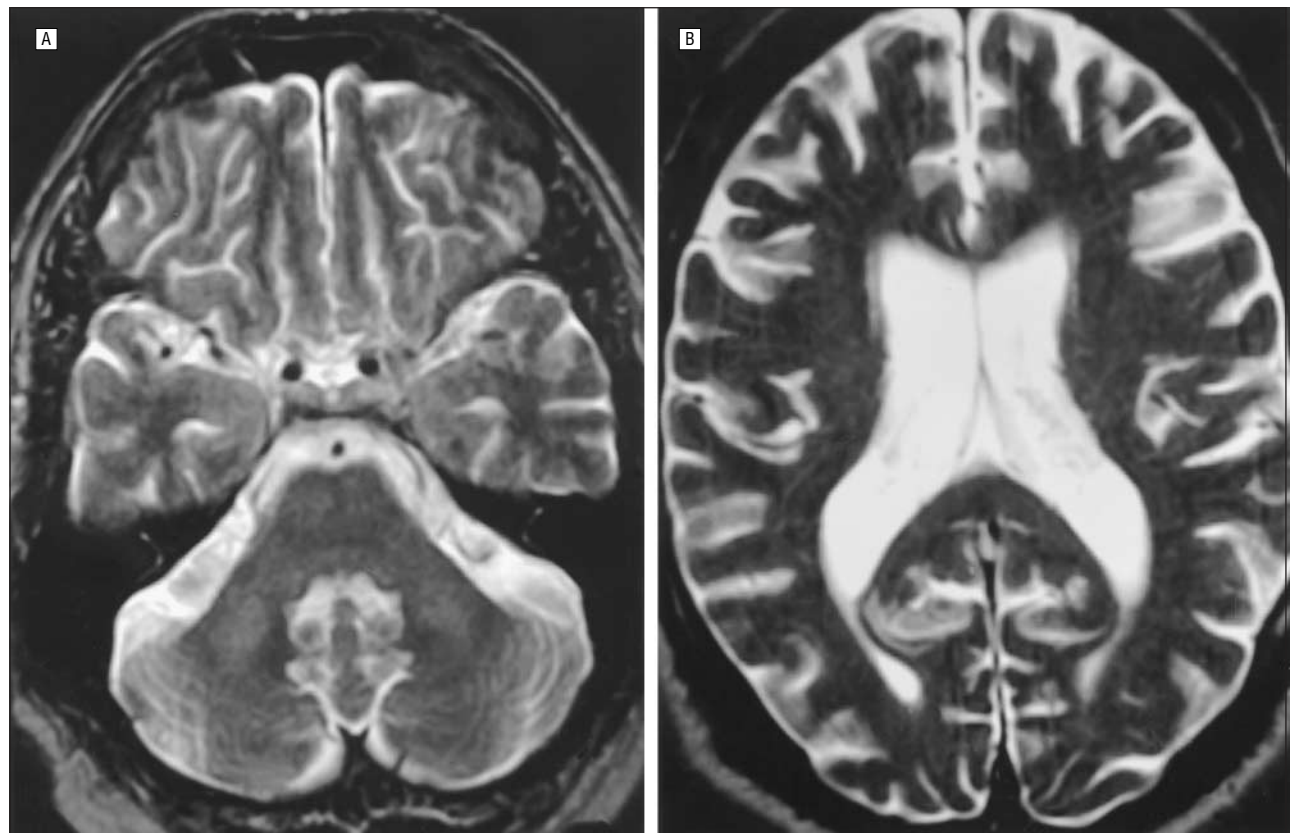
General physical examination findings were notable for normal blood pressure without abnormal orthostatic changes, round face without prominent ears,



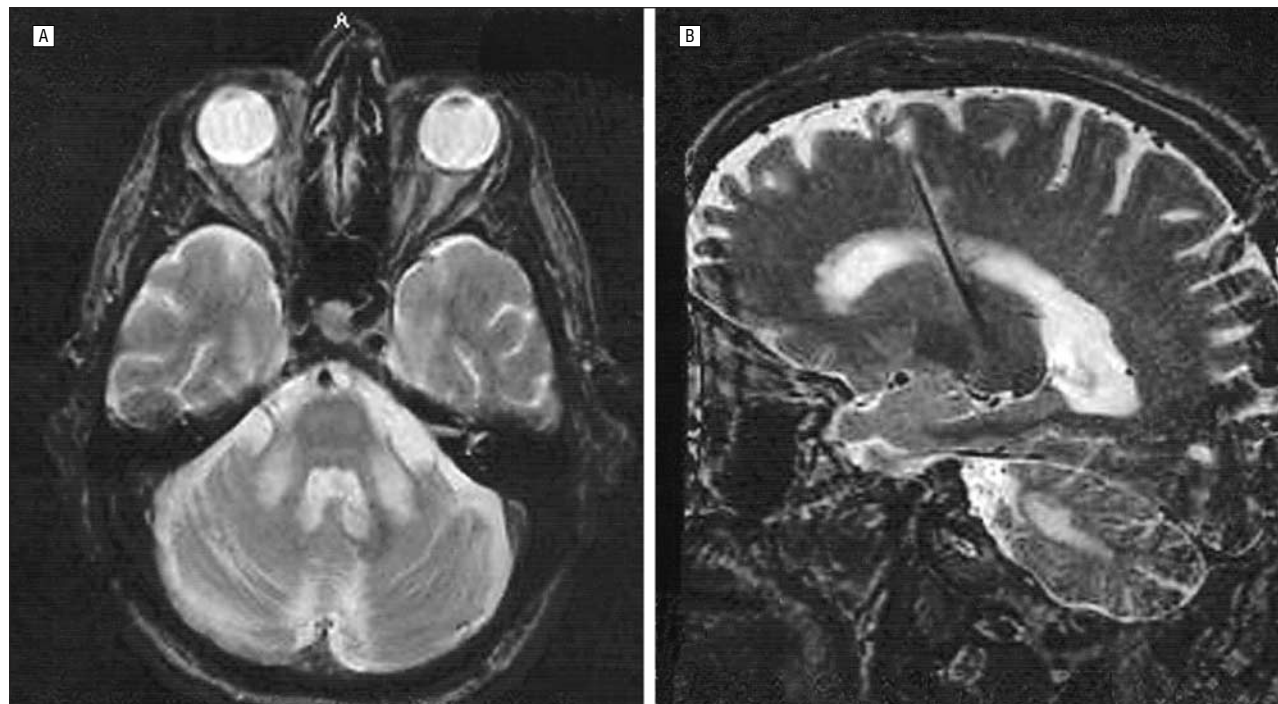
**Figure 1.** Handwriting sample and Archimedes spiral drawing from patient 1. Patient 1 was asked to write and to connect the dots with his dominant hand, using a Clinical Tremor Rating Scale form developed by Fahn and colleagues.<sup>2</sup>

and borderline large testicular volume of 35 mL. He was cheerful and outgoing. His handwriting and drawing samples are shown in **Figure 1**.<sup>2</sup> Cranial nerve findings were normal. He had a subtle, intermittent, “no” head tremor and a small-amplitude, slow, distal postural and intention tremor of the upper extremities (left greater than right). Tone was slightly reduced and rebound mildly increased in the upper extremities. Synergy, trajectory, and placement of upper- and lower-extremity movements were normal. Facial expression was animated, and he had normal speed and amplitude of movements. Muscular power and muscle stretch reflexes were normal, except the latter were absent at the ankles. Plantar responses were flexor. Vibration sense was reduced moderately in the distal upper extremities and markedly in the distal lower extremities. Position sense was mildly impaired in the left great toe. Gait and stance were normal. He could tandem only 3 or 4 steps without stepping out.

His Wechsler Adult Intelligence Scale III verbal IQ score was 112 and performance IQ, 106. He had particular difficulty with digit span skills (digit forward, 10; digit backward, 3). On the Behavioral Dyscontrol Scale, which is a 9-item, 19-point scale adapted from the work of Luria<sup>3</sup> that measures the capacity to use intentions to regulate purposeful behavior, he was disinhibited on a go–no go task and impaired at motor procedural learning. The patient was tangential and sometimes had difficulty following directions or explanations. Overall, executive functioning was mildly to moderately impaired. Brain magnetic resonance images (MRIs) are shown in **Figure 2**.



**Figure 2.** Brain magnetic resonance images (MRIs) of patient 1. Axial T2-weighted MRIs. A, In the middle cerebellar peduncles and in white matter of the cerebellum lateral to the dentate nuclei, there is slightly increased T2 signal intensity. The pons appears normal. B, There is mild prominence in the size of the lateral ventricles and a mild prominence in the size of the sulci over the frontal and parietal cortex consistent with diffuse volume loss.



**Figure 3.** Brain magnetic resonance images (MRIs) of patient 2. A, Axial T2-weighted MRI scan shows bilateral symmetric hyperintense signal involving the middle cerebellar peduncles. B, The sagittal view shows the DBS lead, enlarged lateral ventricle, and hyperintense signal involving the middle cerebellar peduncles and cerebellar white matter.

Fragile X testing showed a fragile X mental retardation 1 (*FMRI*) gene CGG repeat expansion of 90 and elevated messenger RNA (mRNA) at  $2.38 \pm 0.19$  (SEM) times normal.<sup>4</sup> Fragile X mental retardation protein (FMRP) level<sup>5</sup> was slightly reduced ( $\geq 72\%$  FMRP lymphocytes).

#### PATIENT 2

A healthy, 63-year-old, right-handed former truck driver was diagnosed as having ET at age 49 years. By age 59 years, he was dependent on his wife to perform some activities of daily living.  $\beta$ -Blockers and primidone offered mild tremor reduction in the first weeks of treatment, but benefit waned and tremor severity progressed. An occasional glass of wine provided mild subjective improvement. His mother and brother had also been diagnosed as having ET. Childhood and adolescent development were normal.

Neurologic examination findings revealed an asymmetrical (right greater than left), high-amplitude, low-frequency postural and action tremor that affected the upper and lower extremities. There was no clear superimposed ataxia in the limbs, especially the legs, where it could be more reliably assessed. He had a low-amplitude, variable motor head tremor. Handwriting was large and illegible. Tone, strength, deep tendon reflexes, and sensation were normal. Gait and stance were normal, but there was marked instability in tandem gait.

In April 1998, the patient underwent implantation of bilateral Vim thalamic electrodes using microelectrode guidance. After surgery, his limb tremor had completely resolved due to a profound "microthalamotomy" effect, and therefore deep brain stimulators were not turned on. His head tremor also decreased signifi-

cantly. However, immediately after surgery his balance worsened, resulting in repeated falls, especially when walking longer distances. His speech also became "slower." In August 1998, his limb tremor recurred bilaterally. Electrophysiologic testing suggested malfunction of the left system due to an open circuit (ie, broken cable). On the right, suboptimal electrode placement was suggested by MRI and programming results. We decided not to operate again (ie, replace the left electrode or relocate the right) because of concern that his gait and speech might worsen further. His postoperative brain MRI is shown in **Figure 3**.

Finding that his grandson has fragile X syndrome, the patient underwent fragile X genetic testing. His *FMRI* gene had 160 CGG repeats, *FMRI* mRNA was elevated ( $5.5 \pm 0.50$  times normal), and FMRP was reduced ( $\geq 61\%$  lymphocytes).

#### COMMENT

Fragile X syndrome, the most common known cause of inherited mental retardation, results from expansion of a CGG trinucleotide repeat expansion in the 5'-untranslated region of the *FMRI* gene.<sup>6,7</sup> Normally, *FMRI* has 6 to 40 CGG repeats. Forty-one to 54 repeats is considered "gray zone," and "premutation" carriers have 55 to 200 repeats. The full mutation, which involves more than 200 repeats, results in methylation and transcriptional silencing of the gene.<sup>8,9</sup> The full mutation phenotype is variable; common manifestations include mental retardation, autism, hyperactivity, learning disabilities, and physical stigmata, such as long face, large ears, and macroorchidism.<sup>10</sup> The severity of the cognitive deficit correlates inversely with the FMRP level.<sup>5</sup> Males are more

affected than females, since females have a second X chromosome that produces FMRP.

Carrier frequencies are estimated to be 1 per 260 females and 1 per 760 males,<sup>11,12</sup> although newer studies suggest that the frequencies may approach 1 per 100.<sup>13,14</sup> Male carriers with alleles in the low premutation range (55-100 repeats) have *FMR1* mRNA levels 2 to 4 times above normal, despite near-normal levels of FMRP; male carriers with 100 to 200 CGG repeats have mRNA levels 4 to 10 times normal, despite mildly reduced FMRP levels.<sup>15,16</sup> Female carriers also have elevated mRNA levels.<sup>15</sup> Premutation carriers have, until recently, generally been considered phenotypically normal. Some carriers show physical features of fragile X syndrome<sup>17,18</sup> and/or mild emotional and cognitive problems.<sup>19</sup>

The carrier state is also associated with symptoms not associated with the full mutation. Premature menopause occurs in approximately 20% of women,<sup>20</sup> and some older men develop a tremor/ataxia syndrome,<sup>1</sup> which is the focus of this article. This syndrome is characterized by progressively disabling intention tremor, cerebellar gait ataxia, erectile dysfunction, peripheral neuropathy, social anxiety, anger outbursts, mild parkinsonism, and dementia. Brain imaging reveals generalized brain atrophy in all cases, and MRI shows T2 hyperintensities of the middle cerebellar peduncles, as shown in Figures 2 and 3, in most cases.<sup>21</sup> Neuropathologic analysis shows neuronal and astrocytic intranuclear inclusions throughout the cerebrum and cerebellum, most numerous in the hippocampus. In the cerebellum, there was marked dropout of Purkinje cells and dystrophic cerebellar white matter changes.<sup>22</sup> The pathogenesis of this syndrome may result from increased *FMR1* mRNA levels, perhaps in conjunction with other as-yet-undefined gene effects. The increased mRNA levels may result from reduced translational efficiency of the *FMR1* mRNA, which begins in the premutation range.

Our 2 patients were originally misdiagnosed as having ET, which is the most prevalent adult movement disorder and one of the most common adult neurologic disorders.<sup>23</sup> Despite methodologic difficulties and various biases, the most reliable epidemiologic studies report a prevalence that ranges from 0.01% to 4.02% in the total population and from 1.10% to 5.55% for those older than 39 years.<sup>24</sup> Distribution is similar in males and females and incidence increases with age. The typical age of onset is 35 and 45 years, with 18% of cases occurring as late as the sixth decade of life.<sup>25</sup> Although the postural tremor is considered typical of ET, in fact action (kinetic) tremor, as seen in the patients described herein, is often more prominent and is the cause of disability in this disorder.<sup>26</sup> Often, ET has been considered a monosymptomatic disorder, but additional neurologic abnormalities have been emphasized recently. Tandem gait abnormalities indistinguishable from those of cerebellar diseases (increased number of missteps and broad-based, ataxic, and dysmetric gait) have been demonstrated, which correlate with increased age, the presence of intention tremor, and greater interference with daily activities.<sup>27,28</sup> Cognitive deficits (verbal fluency, naming, mental-set shifting, verbal and working memory) and higher levels of depression have also been described re-

cently in patients with disabling ET.<sup>29,30</sup> However, as outlined herein, some of these same findings occur in elderly male carriers of fragile X,<sup>1</sup> suggesting that some of the ET patients involved in these studies may in fact have the fragile X premutation.

The fragile X premutation tremor/ataxia syndrome is newly described and is in the process of being characterized. Some affected persons have little or no action tremor and may have resting tremor. Some have mild parkinsonian features. Evidence to date suggests that all develop cerebellar gait ataxia and cognitive disturbances. What fraction of male and female carriers develop this syndrome is unknown.

This syndrome has been previously given a variety of diagnostic labels, including ET, spinocerebellar ataxia, atypical parkinsonism, and olivopontocerebellar atrophy. Clinicians should consider testing for the fragile X premutation in patients with action tremor, progressive cerebellar gait ataxia, or parkinsonism with cerebellar features, especially if frontal executive deficits or middle cerebellar peduncle hyperintensities on T2-weighted MRI are present. We suggest consideration of this diagnostic possibility in patients thought to have ET who are considered to be candidates for neurosurgery and recommend a cautious evaluation of the risk-benefit ratio of surgery in individuals who carry the premutation.

Accepted for publication June 18, 2002.

**Author contributions:** Study concept and design (Drs Leehey, Lang, and P. Hagerman); acquisition of data (Drs Leehey, Munhoz, Lang, Grigsby, Greco, Tassone, Lozano, and R. Hagerman); analysis and interpretation of data (Drs Leehey, Brunberg, Greco, Jacquemont, and R. Hagerman); drafting of the manuscript (Drs Leehey, Munhoz, Lang, Brunberg, Greco, and P. Hagerman); critical revision of the manuscript for important intellectual content (Drs Munhoz, Lang, Brunberg, Grigsby, Greco, Jacquemont, Tassone, Lozano, P. Hagerman, and R. Hagerman); obtained funding (Drs Leehey and R. Hagerman); administrative, technical, and material support (Drs Munhoz, Lang, Brunberg, Grigsby, Jacquemont, Tassone, Lozano, and P. Hagerman); study supervision (Drs Lang and R. Hagerman).

This study was supported by grant HD36071 from the National Institute on Deafness and Other Communication Disorders, Bethesda, Md, grant MO1 RR00069 from the General Clinical Research Centers Program, Denver, Colo; National Center for Research Resources, National Institutes of Health, Bethesda; and the M.I.N.D. Institute.

Corresponding author and reprints: Maureen A. Leehey, MD, Department of Neurology, University of Colorado Health Science Center, 4200 E Ninth Ave, Box B183, Denver, CO 80262 (e-mail: maureen.leehey@uchsc.edu).

## REFERENCES

1. Hagerman RJ, Leehey M, Heinrichs W, et al. Intention tremor, parkinsonism, and generalized brain atrophy in male carriers of fragile X. *Neurology*. 2001;57:127-130.
2. Fahn S, Tolosa E, Marin C. Clinical rating scale for tremor. In: Jankovic J, Tolosa E, eds. *Parkinson's Disease and Movement Disorders*. Baltimore, Md: Urban & Schwarzenberg; 1998:225-234.

3. Luria AR. *Higher Cortical Functions in Man*. 2nd ed. New York, NY: Basic Books; 1980.
4. Tassone F, Hagerman RJ, Taylor AK, Hagerman PJ. A majority of fragile X males with methylated, full mutation alleles have significant levels of FMR1 messenger RNA. *J Med Genet*. 2001;38:453-456.
5. Tassone F, Hagerman RJ, Iklé DN, et al. FMRP expression as a potential prognostic indicator in fragile X syndrome. *Am J Med Genet*. 1999;84:250-261.
6. Verkerk AJ, Pieretti M, Sutcliffe JS, et al. Identification of a gene (FMR-1) containing a CGG repeat coincident with a breakpoint cluster region exhibiting length variation in fragile X syndrome. *Cell*. 1991;65:905-914.
7. Yu S, Pritchard M, Kremer E, et al. Fragile X genotype characterized by an unstable region of DNA. *Science*. 1991;252:1179-1181.
8. Oberlè I, Rousseau F, Heitz D, et al. Instability of a 550-base pair DNA segment and abnormal methylation in fragile X syndrome. *Science*. 1991;252:1097-1102.
9. Pieretti M, Zhang FP, Fu YH, et al. Absence of expression of the FMR-1 gene in fragile X syndrome. *Cell*. 1991;66:817-822.
10. Hagerman RJ. The physical and behavioral phenotype: In Hagerman RJ, Hagerman PJ, eds. *Fragile X Syndrome: Diagnosis, Treatment, and Research*. Baltimore, Md: Johns Hopkins University Press; 2002:3-109.
11. Rousseau F, Rouillard P, Morel ML, Khandjian EW, Morgan K. Prevalence of carriers of premutation-size alleles of the FMR1 gene—and implications for the population genetics of the fragile X syndrome. *Am J Hum Genet*. 1995;57:1006-1018.
12. Rousseau F, Morel M-L, Rouillard P, Khandjian EW, Morgan K. Surprisingly low prevalence of FMR1 premutation among males from the general population [abstract]. *Am J Hum Genet*. 1996;59:1069.
13. Pessó R, Berkenstadt M, Cuckle H, Peleg L, Frydman M, Barkai G. Screening for fragile X syndrome in women of reproductive age. *Prenat Diagn*. 2000;20:611-614.
14. Toledano-Alhadeff H, Basel-Vanagaite L, Magal N, et al. Fragile X carrier screening and the prevalence of premutation and full mutation carriers in Israel. *Am J Hum Genet*. 2001;69:351-360.
15. Tassone F, Hagerman RJ, Chamberlain WD, Hagerman PJ. Transcription of the FMR1 gene in individuals with fragile X syndrome. *Am J Med Genet*. 2000;97:195-203.
16. Tassone F, Hagerman RJ, Loesch DZ, Lachiewicz A, Taylor AK, Hagerman PJ. Fragile X males with unmethylated, full mutation trinucleotide repeat expansions have elevated levels of FMR1 messenger RNA. *Am J Med Genet*. 2000;94:232-236.
17. Loesch DZ, Hay DA, Mulley J. Transmitting males and carrier females in fragile X—revisited. *Am J Med Genet*. 1994;51:392-399.
18. Riddle JE, Cheema A, Sobesky WE, et al. Phenotypic involvement in females with the FMR1 gene mutation. *Am J Ment Retard*. 1998;102:590-601.
19. Tassone F, Hagerman RJ, Taylor AK, et al. Clinical involvement and protein expression in individuals with the FMR1 premutation. *Am J Med Genet*. 2000;91:144-152.
20. Allingham-Hawkins DJ, Babul-Hirji R, Chitayat D, et al. Fragile X premutation is a significant risk factor for premature ovarian failure: the International Collaborative POF in Fragile X study—preliminary data. *Am J Med Genet*. 1999;83:322-325.
21. Brundberg JA, Jacquement S, Hagerman RJ, et al. Fragile X premutation carriers: characteristic MR imaging findings in adult males with progressive cerebellar and cognitive dysfunction. *Am J Neuroradiol*. In press.
22. Greco CM, Hagerman RJ, Tassone F, et al. Neuronal intranuclear inclusions in a new cerebellar tremor/ataxia syndrome among fragile X carriers. *Brain*. In press.
23. Kurtze JF. The current neurological burden of illness and injury in the United States. *Neurology*. 1982;32:1207-1214.
24. Brin MF, Koller W. Epidemiology and genetics of essential tremor. *Mov Disord*. 1998;13(suppl 3):55-63.
25. Lou JS, Jankovic J. Essential tremor: clinical correlates in 350 patients. *Neurology*. 1991;41:234-238.
26. Brennan K, Jurewicz E, Ford B, Pullman S, Louis E. Is essential tremor predominantly a kinetic or a postural tremor? a clinical and electrophysiological study. *Mov Disord*. 2002;17:313-316.
27. Hubble JP, Busenbark KL, Pahwa R, Lyons K, Koller WC. Clinical expression of essential tremor: effects of gender and age. *Mov Disord*. 1997;12:969-972.
28. Stolze H, Petersen G, Raethjen J, Wenzelburger R, Deuschl G. The gait disorder of advanced essential tremor. *Brain*. 2001;124:2278-2286.
29. Gasparini M, Bonifati V, Fabrizio E, et al. Frontal lobe dysfunction in essential tremor: a preliminary study. *J Neurol*. 2001;248:399-402.
30. Lombardi WJ, Woolston DJ, Roberts JW, Gross RE. Cognitive deficits in patients with essential tremor. *Neurology*. 2001;57:785-790.